

# BASIC MICROSURGICAL TECHNIQUES

Microsurgery Training Laboratory

National University Hospital

Singapore

**Authors****Dr Amitabha Lahiri**

Senior Consultant

Hand and Reconstructive Microsurgery

National University Hospital

Singapore

**Dr.Sandeep J Sebastin**

Senior Consultant

Hand and Reconstructive Microsurgery

National University Hospital

Singapore

**Ms. Siti Khadijah**

Instructor,

Microsurgery Training laboratory

National University Hospital

Singapore

**Dr.Ellen YT Lee**

Associate Consultant

Hand and Reconstructive Microsurgery

National University Hospital

Singapore

**Dr. Alphonsus KS Chong**

Senior Consultant

Hand and Reconstructive Microsurgery

National University Hospital

Singapore

## Table of Contents

Microsurgical Techniques.....	4
Handling Microsurgical Instruments .....	4
General Techniques And Principles Of Micro-Vascular Anastomosis.....	7
Vessel And Tissue Handling: .....	7
Preparation Of Vessels For Anastomosis .....	7
Suturing Techniques For Achieving End To End Anastomosis .....	9
The 180° Technique:.....	9
Back-Wall-First Technique: .....	9
Triangulation Technique .....	9
Microsurgical Suture Placement: Basic Technique .....	10
Terminology:.....	10
Loading The Needle On The Needle Holder .....	11
The Technique For Placement Of A Standard Microsurgical Stitch .....	12
Technique Of ‘Flipping ‘The Vessel Over.....	15
Placing The Back-Wall Stitches .....	16
Optimal Number Of Sutures: .....	20
Preparation Of Training Models .....	21
Preparation Of Chicken Thigh For Microvascular Anastomosis On The Femoral Neurovascular Bundle.....	21
( Video Link : <a href="https://Vimeo.Com/Channels/Microsurgery">https://Vimeo.Com/Channels/Microsurgery</a> ) .....	21
Rat Femoral Artery.....	23
Technique For Exposure And Suturing For The Femoral Vessles .....	25
Summary .....	31



## MICROSURGICAL TECHNIQUES

### Handling Microsurgical Instruments


Micro-instruments are designed to be held like a pen to allow for precise manipulation of the needle, the suture and the tissues.

The forceps are held in the non-dominant hand whereas the needle holder and scissors are held in the dominant hand.


When operating alone the surgeon must learn to efficiently exchange the needle-holder and the scissor in the dominant hand while placing sutures.

The micro-instruments are always held in a chuck grip with the ulnar border of the hand resting on a stable surface. This position allows precise control of instruments while minimising tremors. There are a number of situations particularly when performing anastomoses in depth such as the head & neck region or the abdomen, where this position may not be possible and the surgeon will need to improvise, and adapt.

The movements that can be achieved using this grip are the rolling movements between the finger tips (rotation around the axis of the instrument) as well as movements at the wrist without lifting the ulnar border from the resting surface



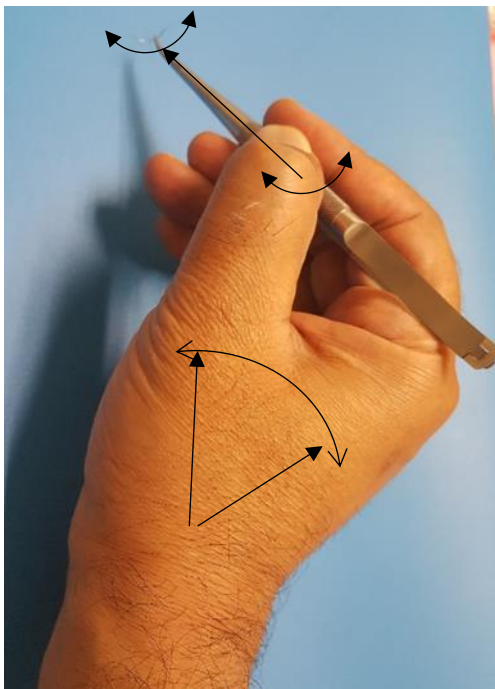
The picture above shows the 'chuck' grip used for holding the forceps (left) and the needle holder(right)




The pictures above show how stability is achieved by pacing the ulnar border of the hand and the little fingers on a rigid surface

### Manipulation of the Needle holder

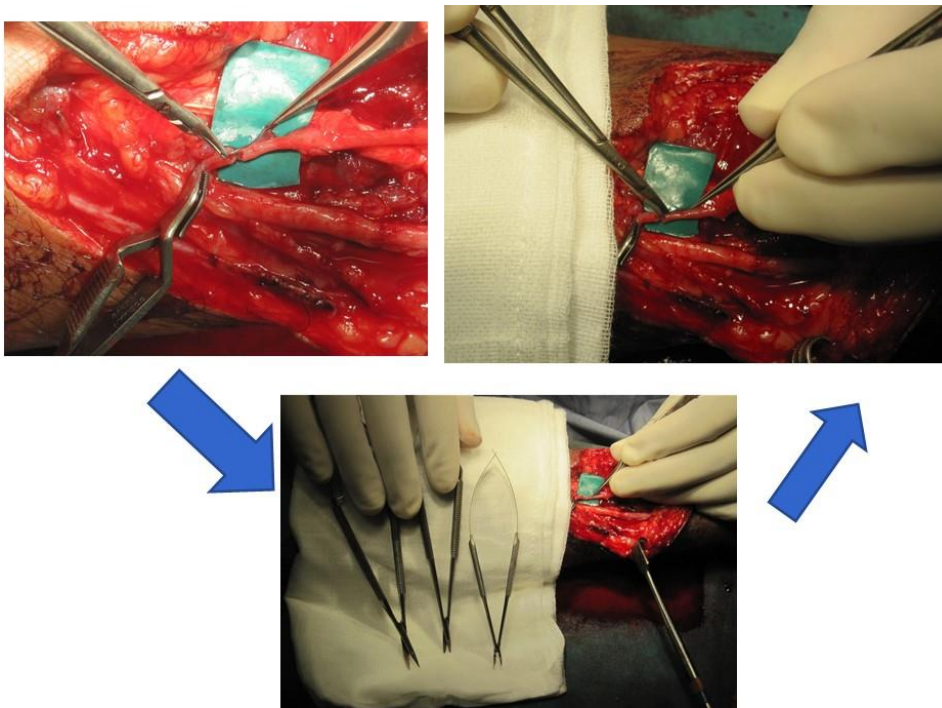
A precise control over the needle holder ensures smooth passage of the needle through the vessel wall without creating tears.



The arc of rotation for insertion of the needle can be achieved through a rolling motion of the needle holder assisted by small movements of the wrist without lifting the hand off the resting surface



Above: Complete arc for needle insertion can be achieved by the rolling motion of the needle holder. The thumb is gradually extended to roll the needle holder against the side of the index finger without loosening the grip on the needle.



Exchanging instruments while operating alone:

Top left: placement of stitch using the needle holder in the right hand, Bottom: the needle holder returned to the instrument area on the right side of the field and the scissors is picked up. The left hand continues to hold the forceps. ( for the right handed surgeon)

## GENERAL TECHNIQUES AND PRINCIPLES OF MICRO-VASCULAR ANASTOMOSIS

### Vessel and tissue handling:

Small blood vessels need to be handled with extreme care. Small, undetected trauma to the wall or the intima may initiate vasospasm or thrombosis resulting in failure of the entire procedure.

As a general rule, vessels are never grasped with any instrument. The vessels are always handled by grasping the adventitia alone. As an exception to the rule, prior to the anastomosis, the injured end that needs to be excised can be held with forceps but it must be ensured that, the part that was grasped has been excised.

### Preparation of vessels for anastomosis:

Excision of adventitia: the adventitia surrounding the vessel should be excised to prevent its entrapment into the lumen during the anastomosis.

Small segments of adventitia should be held with jewelers' forceps and excised without damaging the underlying media.

If the media is inadvertently injured, that segment should be excised.

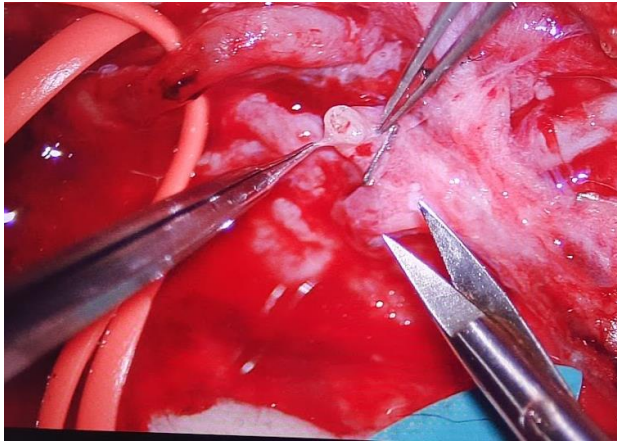
Freshening of vessel ends: the vessel ends should be cut to a point when healthy vessel wall and a clear lumen is visible. Contused edges tears should be excised and any branches close to the edge should be ligated or preferably eliminated by further excision.

Irrigation: the lumen should be irrigated with a heparin-saline solution to wash away any clots and to prevent the formation of new clots.

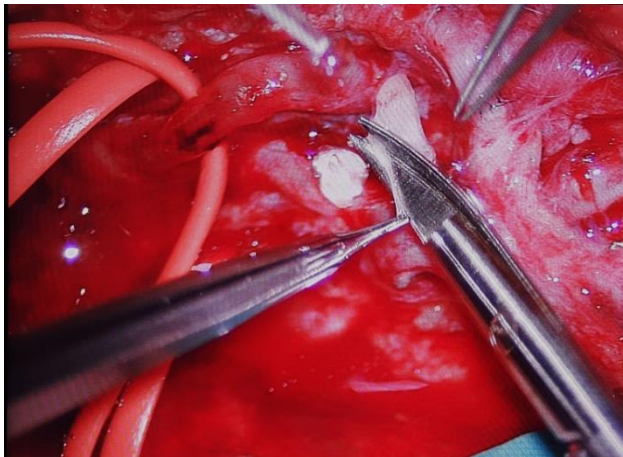
Approximation: Approximation of vessel edges is achieved by using approximator clamps. It should be noted that the vessel ends can be approximated without any tension. If undue force is needed to approximate the edges, also indicated by cutting-out of sutures or suture breakage, the tension should be relieved by further mobilization of the vessel or a vein or an arterial graft should be used.

An anastomosis under tension is likely to fail.

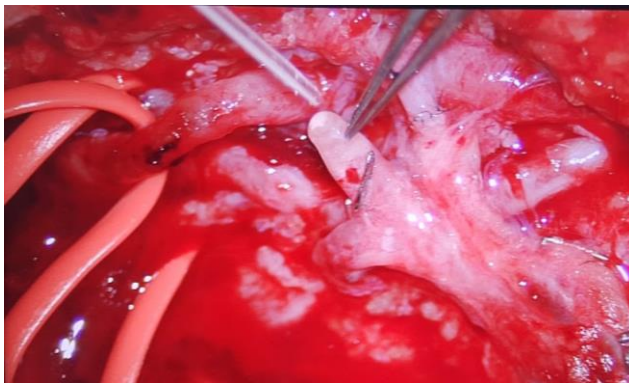




The vessel is held with the adventitia using Jeweller's forceps.



The adventitia is excised using the curved micro-scissors



The prepared vessel is irrigated with heparinised saline to flush out blood or thrombi from the lumen

## SUTURING TECHNIQUES FOR ACHIEVING END TO END ANASTOMOSIS

The commonly used techniques are, the 180° technique and the back-wall-first technique.

**The 180° technique:**

This is the most commonly used technique for end-to-end anastomosis

After the approximation of the vessel ends using an approximator-clamp, the first two sutures are placed at the top and the bottom of the edges (representing two points on the circumference 180° apart. Following these sutures, equidistant sutures are placed to suture the top half of the circumference.

The approximator-clamps are then flipped to expose bring the bottom half of the circumference into view, which is sutured as described earlier.

The clamps are then removed to check for blood flow across the anastomosis and for leaks. Leaks can be closed using additional sutures.

The main precaution is to prevent inadvertently suturing the opposite wall.

**Back-wall-first technique:**

This technique involves suturing the bottom-half of the circumference using inverted suturing technique first followed by suturing the top half of the vessel. The advantage of this technique is that it does not require the step of flipping the approximator clamp, particularly in areas where space is constrained. This technique can also be performed without approximator clamps. It also requires a higher level of skill for accurate placement of inverted sutures.

**Triangulation technique:** This technique involves initial placement of three sutures 120° apart on the circumference of the vessel, followed by sequential suturing of each of the three segments. This technique is rarely used in microvascular surgery. It is a more common technique in vascular surgery involving large vessels.

## Microsurgical Suture placement: Basic technique

The techniques are demonstrated using rubber tubing for clarity.

**Terminology:** The front wall refers to the superficial half of the circumference that is visible to the surgeon. The back wall refers to the deeper half of the circumference that is away from the surgeon.

The technical aspect that must be strictly adhered- to is, that, the forceps should not be used to grasp or crush the vessel wall. It should only be used to grasp the adventitia of the vessel or to provide a counter-pressure for needle insertion.


The second technical consideration is the insertion of the needle. The needle should penetrate the vessel wall neatly without any side-to side motion. Any tremor or redundant motion during penetration of the wall will result in a laceration, subsequently resulting in a leak or thrombosis.

Suture placement can be divided into 4 steps


- Loading the needle correctly on the needle holder
- Passing the needle through the vessel wall
- Pulling the thread through
- Tying the knot and proceeding to the next stitch

The following illustrations demonstrate the steps


## Loading the needle on the needle holder




The needle is suspended by a short length of the suture so that its tip rests lightly on a clear surface



The needle is then grasped using the needle holder




The forceps is then used to fine-tune the orientation of the needle



The final position with the needle held at 2/3 rds of the circumference and oriented at 90 degrees to the tip.

With growing familiarity with suturing variations of this orientation can be used

## The technique for placement of a standard Microsurgical stitch



The tips of the forceps are inserted into the lumen to lift the vessel wall and to provide a steady counter-pressure. The needle is inserted perpendicular to the wall.




The same is demonstrated in a top-down view in the this photograph




The needle is then passed through the second wall with the forceps providing counter-pressure from the outside. Care is taken not to include the back-wall in the stitch


Care is taken not to catch the back wall during the manoeuvre




The needle is held using the needle holder and controlled traction is applied to pull the suture through while providing a gentle counter-pressure on the vessel




The suture is pulled until about 5mm of the tail of the suture is remaining



The needle is dropped in the field and a short segment of the suture is picked up using the forceps, which is used to make a double throw loop around the needle holder



The end of the suture is grasped using the needle holder and pulled through the loop




The instruments are crossed to create a square knot

The process is repeated with two additional single knots alternated in opposite directions to complete the knot

**A correctly placed suture should bring the edges into approximation without inversion into the lumen. An inversion and the exposure of adventitia or the media to the blood flow may initiate clot formation**

### Technique of 'flipping' the vessel over

In the 180 degree technique, once the 'front-wall' is completely sutured the approximator clamps are used to turn the vessel so that the back wall comes in view. This requires torsion of the vessel and adequate length and space must be available in order to perform this manoeuvre.




Top left: completed 'front-wall', Top right: forceps are used to lift the connecting bar of the approximator clamps. Bottom left and right : completion of the 180 degree turn with the bac-wall coming into view.

The vessel is fixed on both ends (represented by the tape) and undergoes torsion when the clamps are turned as shown. This manoeuvre requires that the vessel is not under tension and adequate space is available around the clamps to complete the rotation.




## Placing the Back-wall stitches




The adventitia of the vessel is grasped using a jeweller's forceps to bring the back wall in view.

The needle is inserted in the 'outside-in' direction perpendicular to the wall.


The first suture may be placed at the 6 o'clock position or some surgeons may prefer to start at the 5 o'clock position



The distal part of the needle is pulled through, with a short length of the suture



The segment of the suture is held using the forceps to re-grasp the needle in the correct orientation




The back wall of the opposite side is brought in view using the jewellers forceps and the needle is passed in the inside-out direction



The suture is pulled in a controlled fashion until about 1cm of the tail end remains

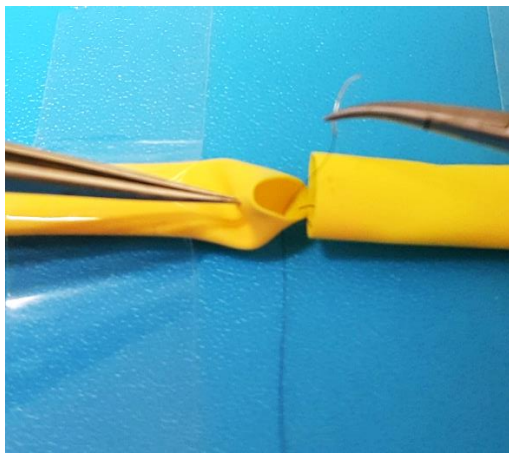


The suture is then picked up to place a double throw knot followed by two single throw knots alternating in opposite directions




The subsequent suture is placed at the 7'oclock position followed by the 4'oclock position


The forceps is used to manipulate the vessel in order to bring the back wall in view




The needle is passed in the same manner as described earlier




The segment of the suture is held and the needle is re-grasped in preparation for re-entry




The wall of the opposite end of the vessel is held by the forceps to bring the back-wall in view




The needle is passed in the inside-out direction



The needle is pulled through



The suture is pulled until a short tail remains



The knot is completed

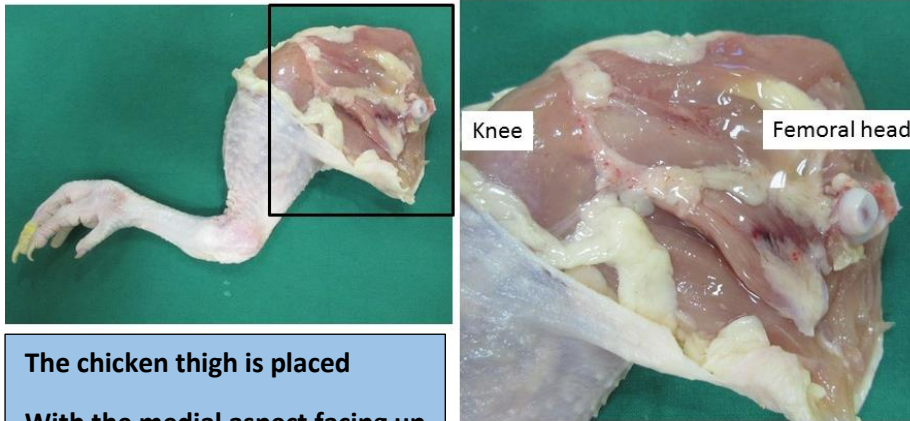
#### Optimal number of sutures:

There is no rigid rule, but for vessels of 1 to 1.2 mm diameter an average seven to nine sutures are needed. The sutures should be placed uniformly and should be spaced such that there are no leaks from the segments between the sutures.

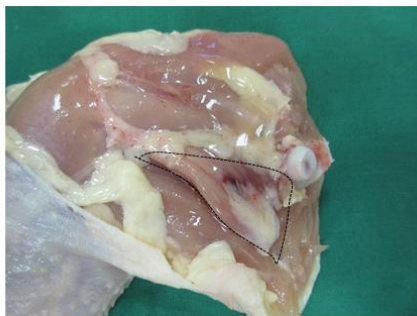## PREPARATION OF TRAINING MODELS

Preparation of Chicken thigh for microvascular anastomosis on the femoral neurovascular bundle.

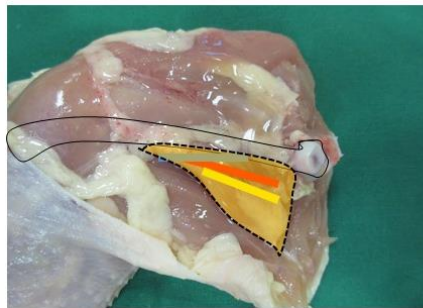
( video link : <https://vimeo.com/channels/microsurgery>)



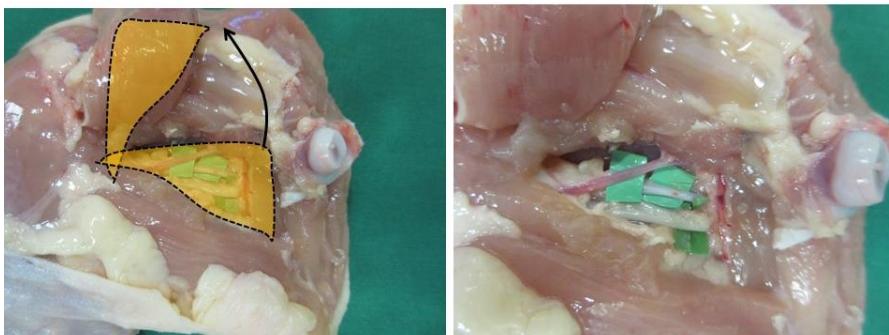
The chicken thigh is placed  
With the medial aspect facing up



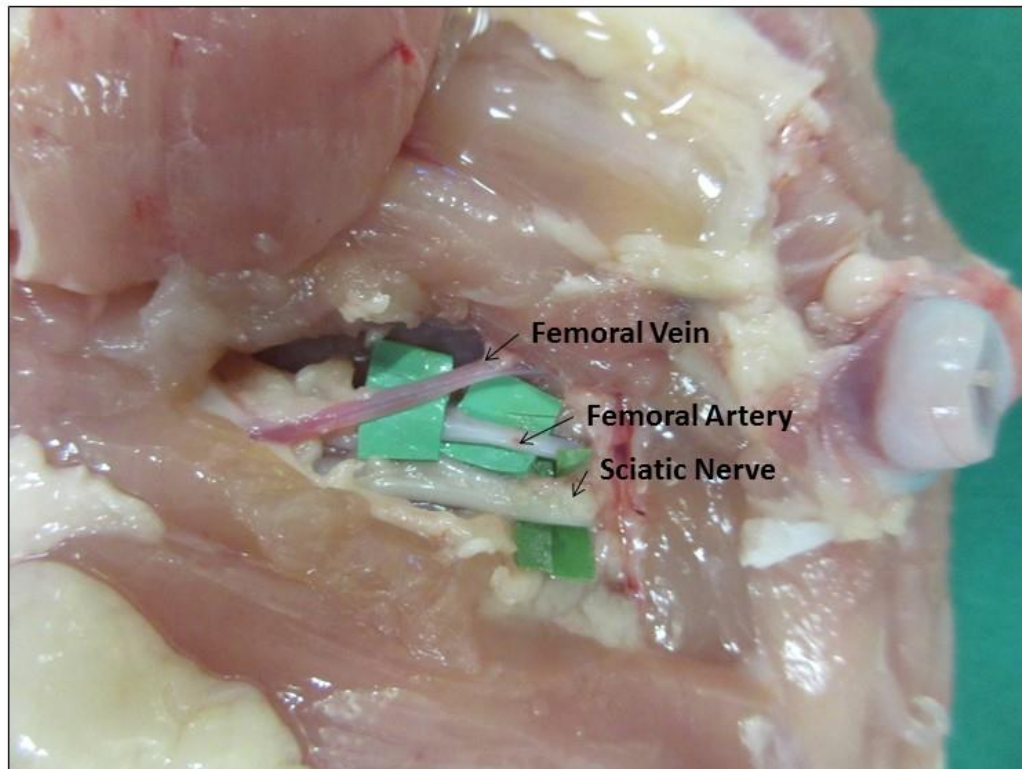
Note the triangular muscle Immediately  
posterior to the femur



The femoral vessels and the sciatic nerve  
are located deep to this triangular muscle



The triangular muscle flap is elevated  
To expose the femoral vessels and the  
Sciatic nerve



**Completed specimen showing the femoral vein artery and the nerve.**

**The specimen is placed under the microscope. The vessels are then divided and anastomosed using 9-0 or 10-0 sutures**

### Rat femoral artery

Rats and mice are used for microsurgical training in several centres around the world, however serious ethical considerations must be given for the use of live animals. The labs and personnell must be duly accredited by the respective institutional boards and attempts must be made t minimise the number of animals used for training.

This is the most common model for end to end arterial anastomosis and vein grafting. It is 1mm in diameter and 1.5cm long from the inguinal ligament to where it branches into superficial and deep. The common femoral artery lies lateral to the vein in the perivascular sheath with the femoral nerve lateral to it. Just before it divides, it gives off the epigastric artery. The epigastric artery has an accompanying epigastric vein that is used for end to side anastomosis training with the femoral artery.

#### **Detailed Procedure:**

With the anaesthetized rat supine on the board, make an oblique incision between the abdomen and the hind leg. Take care to incise just the skin, exposing the inguinal fat pad underneath. Apply wire hook retractors to keep the wound open.

Reflect the inguinal fat pad laterally by cutting through the fat in the upper, medial and lower margins of the wound with micro-scissors. Use bipolar cautery for haemostasis. Visualize the vessel end before cauterizing

Make sure that bleeding is stopped by the grip of the bipolar forceps before applying the current. Lift up the medial edge of the fat pad and pull it laterally. Incise the adherent thin film of tissue underneath, keeping most of it on the fat pad. Dissecting from medial to lateral, the epigastric vessels would be seen entering the fat pad. These vessels should be preserved. The common femoral vessels are seen in the limb once the fat pad is adequately mobilized.

The entire length of the common femoral artery is exposed by blunt dissection. Use moist gauze pieces to push the abdominal wall away from the leg, until the shiny inguinal ligament comes into view. Apply wire hooks to the abdominal wall just above the vessels and secure it with elastic bands across the body of the rat. Achieve a bloodless field at this point before proceeding with vessel dissection.

Use Ringer's solution to keep the wound moist.

Using jeweller's forceps and micro-scissors, excise any loose connective tissue overlying the perivascular sheath. The perivascular sheath is that layer which is not easy to pick up with forceps. Incise the perivascular sheath to expose the artery and vein. The perivascular sheath is then dissected off the artery from proximal to distal, until where the epigastric artery branches. Use jeweller's forceps to pick up the sheath laterally and use the curved micro-scissors with its blade flat on the artery to separate the sheath from the artery. Keep scissor blades parallel to the artery and do not cut what you cannot see. There is a vasa-vasorum around the artery and any bleeding



should be controlled with a bipolar prior to continuing with the dissection. Remember to keep the wound moist by irrigating it with Ringer's solution periodically.

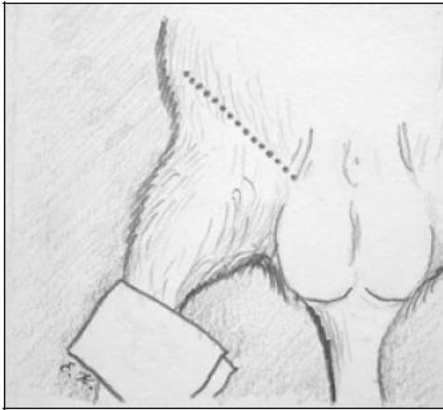
Check your jeweller's forceps to make sure it is clean and the jaws are closing properly. Pick up the artery by its adventitia only with your non-dominant hand. This is the loose white fibrous tissue around the vessel. Take care not to pinch the entire thickness of the vessel wall. Clear the vascular sheath from the entire circumference of the artery using round-tipped micro-scissors. Remember to keep your scissor blades flat on the vessel while working. There is at least one large deep branch arising from the common femoral artery going into the muscles midway between the inguinal ligament and the epigastric artery branch. Lift the common femoral artery to one side and dissect around the deep branch for adequate length away from the common femoral artery. This will allow ample space to ligate & divide or cauterize and divide the branch without damaging the common femoral artery. Dissect the common femoral artery free from the inguinal ligament until the epigastric artery branch. Apply 1% lignocaine and wait three minutes to reverse vasospasm before clamping the vessel.

Use a blue or green-coloured material for background as the artery is almost translucent once cleared of blood. Apply a maximally spread double clamp approximator one end at a time with the clamp applicator. Pick up the vessel in between the clamps, loosen one end then pull a length of the vessel in between the clamps to allow redundancy. If the ligated branch falls near the centre of the clamps, the segment of artery from which it branches can be excised for end-to-end anastomosis. If not, a transverse cut can be made at the centre for ease of anastomosis.

Prepare each cut end of the vessel of anastomosis by washing out the blood, removing the adventitia, and dilating it. The adventitia hangs loosely around the vessel end like a shirt sleeve. Pick up the adventitia of one end and irrigate the vessel end with a fine jet of Ringer's solution. It is not necessary to cannulate the vessel end to clear the blood from it. Then carefully excise the fluffy white fibers around the vessel ends by picking them up with jeweller's and cutting them off with micro-scissors. Trim all adventitia hanging over both vessel ends and those that can be easily pulled over the vessel end in its longitudinal axis. Take your time and be patient in this process. Keep the field moist by irrigating intermittently with Ringer's solution. It is important to remove all adventitia from the vessel end in order to see the media clearly when suturing and to prevent the adventitia from falling in the anastomotic line. Once the media is well delineated, dilate the vessel end by picking the end up with jeweller's and gently inserting the closed tips of the dilator straight center into the vessel till it is halfway between the end & the clamp. Then slowly open the dilator ends till the vessel is one and a half times its diameter. Maintain the stretch for a second then slowly close the tips before sliding it out smoothly. Do this for both ends then position the clamps such that you have one vessel's width distance between the two ends.

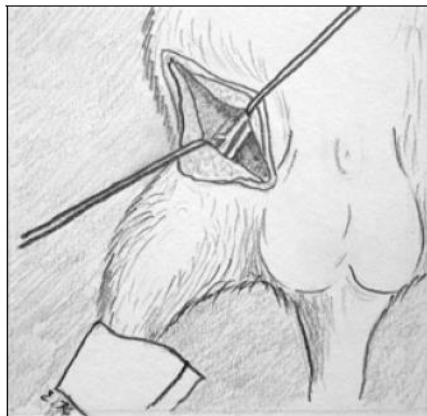
Follow on with the 180 degree suturing technique or the back wall suturing technique as described.

Technique for exposure and suturing for the femoral vessels  
(Illustrations by Elijah Kapickis and Martins Kapickis )



The groin area is shaved

An oblique incision is made in the groin to expose the inguinal fat



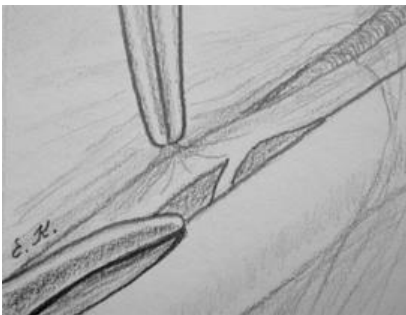A combination of sharp and blunt dissection is performed under the microscope to expose the femoral neurovascular bundle

The skin flaps can be held away using stay sutures or hook retractors with rubber-bands.

## VASCULAR DISSECTION

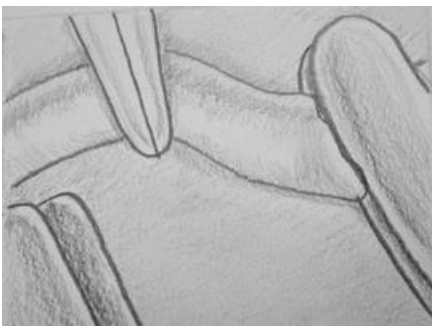

- Incise the perivascular sheath over the artery to free the artery from within it.
- Take hold *only* of the perivascular sheath with the jeweller's forceps over the artery. Dissect it down to the origin of the epigastric artery. When picking up the artery hold only the adventitia.

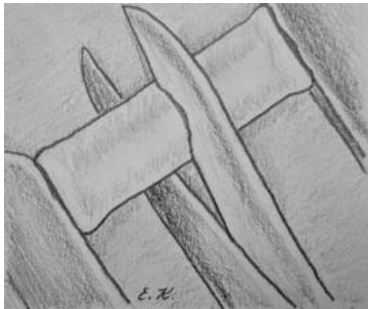


- Free up the femoral vessel from the inguinal ligament until epigastric vessel. Cauterise and divide "Murphy's" branch.

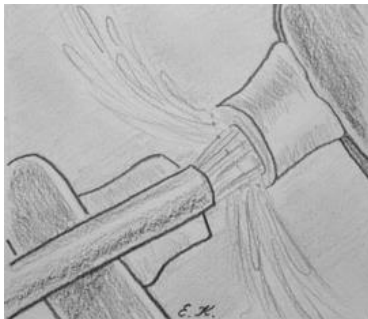## APPLICATION OF VESSEL CLAMPS



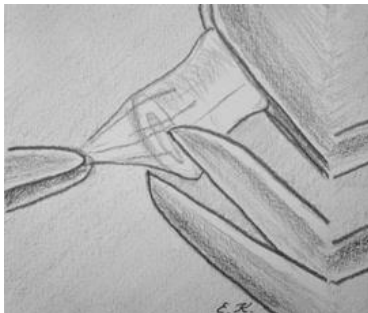- Slip a piece of background material under the artery.
- Pick up double clamp with forceps and open the clip and slip the artery between the jaws of clips.

**PREPARING THE VESSEL****ENDS**

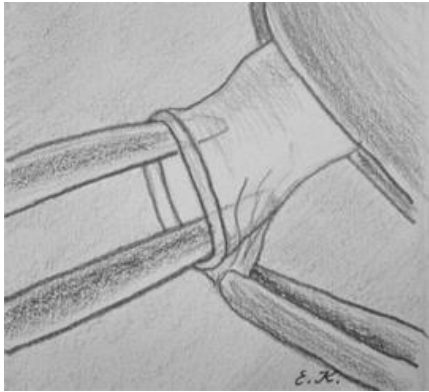
Divide the vessel using sharp straight micro-scissors



Irrigate the vessel immediately with heparinized saline. Hold onto the end of vessel with forceps. Use a blunt-tipped needle or venula to direct the stream into the vessel lumen



Pick up the adventitia with forceps at a point on the vessel end. Pull the adventitia off the end of the vessel and cut through the adventitia with scissors.

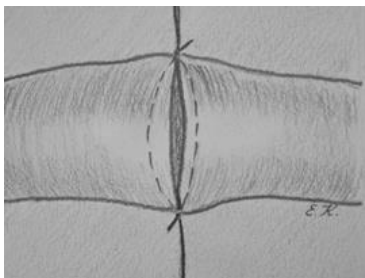


### *Dilating the vessel end.*

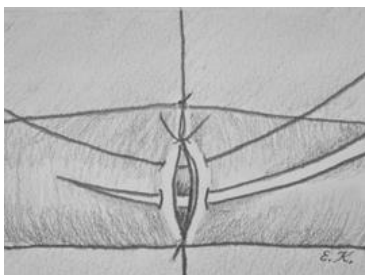
Pick up the vessel close to the end. Insert the closed tip of the dilator into the vessel. Open the vessel dilator until the vessel wall is stretched to natural size. By stretching the smooth muscle of the vessel wall, you paralyze it for the next few hours.

- *To relieve spasm* apply 4 % lidocaine (Xylocaine) to the vessel and wait a few minutes..

### **Suturing: Using the 180 degree technique**

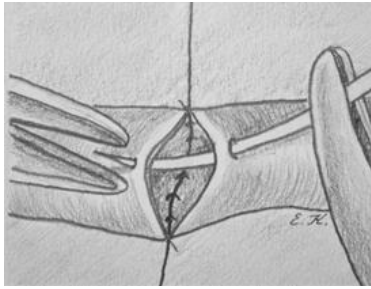


- **Note 1:** The first two sutures are the most important and the most difficult. They must be put at 180° of circumference of vessel. Follow the basic rules that you were taught at the latex sheath board!

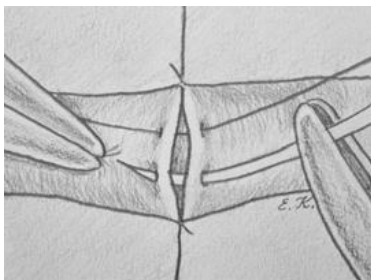


The 'front-wall' or the part of the superficial half of the circumference is sutured with uniformly spaced sutures

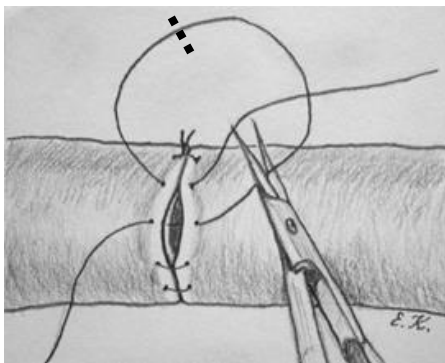
The clamp is then flipped over so that the back wall comes into view



The clamp is now flipped such that the back-wall which is now superficial.



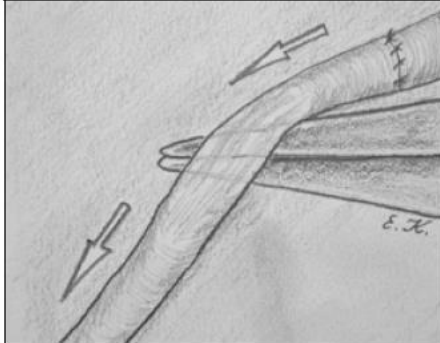
The back wall is sutured using the same technique of forehand sutures



Visualisation of the back wall may be difficult at the last suture, hence two passes are made under vision as a continuous suture and then the suture is divided to create two interrupted sutures that are tied separately

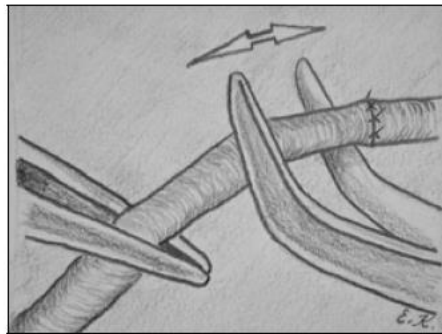
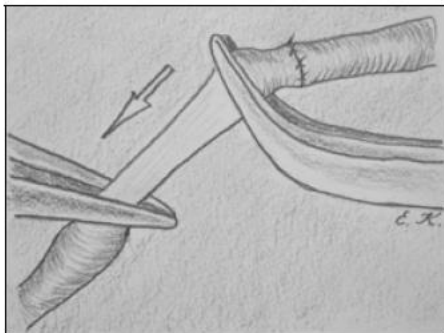
**RELEASING THE CLAMPS:** The distal clamp is released followed by the proximal clamp.

Observe for any leaks from the anastomosis. Place additional sutures if the leak is significant.



Gently lift the distal vessel till it is partially empty due to compression

Pulsatile flow can be visualised through the vessel wall



Gently occlude the vessel downstream to the anastomosis using a pair of jeweller's forceps. Empty the segment downstream to the occlusion using a second pair of forceps by gently grasping and sliding the forceps and then gently occluding the lumen. Release the first forceps. Filling up of the empty segment indicates patency. The same can be performed for the vein taking into account that the venous flow is upstream.

## Summary

Microsurgery training courses impart the technical skills necessary for clinical microsurgery, however performing microvascular surgery in clinical practice requires a considerable amount of experience and clinical judgement and the ability to understand the effects of patients unique physiological condition such as sepsis, diabetes, blood pressure on the outcomes. Similarly a considerable experience is necessary for understanding the effects of trauma, the zone of injury and local infection on the vessels which may compromise the success of a technically perfect anastomosis. These aspects can only be understood and learnt through apprenticeship and clinical training with experienced microsurgeons.

When establishing a training centre legal and ethical approvals are essential which may vary from country to country, similarly the organisers should be cognizant of the moral issues should be familiar with the three R's (reduce, replace and refine) for using animals for training.